



· 论 著 ·

胃癌中RNA解旋酶DDX19A的表达及临床意义

张美智子, 郭佳雯, 周丽丽, 程 玉

承德医学院基础医学院, 河北 承德 067000

[摘要] **背景与目的:** RNA解旋酶DDX19A (DEAD-box helicases 19A)是DDX蛋白超家族的成员之一, 主要参与RNA的转运过程。该家族的许多成员参与肿瘤的发生及发展过程, 然而关于DDX19A在胃癌中的作用, 目前尚未见报道。结合生物信息学分析, 探讨胃癌组织中DDX19A的表达情况及临床意义。**方法:** 采用UALCAN数据库, 转录水平分析胃癌及癌旁胃组织中DDX19A的表达差异, 进一步分析其在胃癌中的表达及与临床分期的关系; 采用Kaplan-Meier Plotter数据库分析DDX19A表达水平与胃癌患者总生存期 (overall survival, OS) 及无病生存期 (disease-free survival, DFS) 的相关性。采用蛋白质印迹法 (Western blot) 检测16对冻存的新鲜胃癌组织及配对癌旁胃黏膜中DDX19A蛋白的表达。收集2011—2015年承德医学院附属医院病理科存档的胃癌石蜡包埋标本109例、癌旁胃黏膜标本30例, 所有患者临床病理学资料完整。免疫组织化学S-P四步法检测109例胃癌及30例癌旁胃黏膜中DDX19A蛋白的表达, 分析其高表达与胃癌临床病理学特征及预后的关系。**结果:** UALCAN及Kaplan-Meier Plotter数据库检索结果显示, DDX19A mRNA在胃癌组织中的表达明显高于癌旁胃组织 ($P<0.01$), 其高表达与胃癌临床分期及患者不良预后正相关 ($P<0.05$)。Western blot结果显示, 胃癌组织中DDX19A蛋白显著高表达 ($P<0.01$)。免疫组织化学结果显示, 胃癌组织中的DDX19A阳性表达率为68.8% (75/109), 显著高于其在癌旁胃黏膜中的表达 (33.3%, 10/30), 差异有统计学意义 ($P<0.01$)。DDX19A高表达与胃癌分化程度、浸润深度、TNM分期密切相关 ($P<0.05$), 而与患者性别、年龄、肿瘤大小、淋巴结转移无关 ($P>0.05$)。69例随访资料完整的病例中, DDX19A高表达患者的OS明显短于低表达患者 ($P<0.05$)。**结论:** DDX19A在胃癌组织中明显高表达, 并且其高表达与胃癌临床分期、侵袭性及患者不良预后相关。DDX19A有望成为与胃癌预后相关的潜在生物标志物及治疗的新靶点。

[关键词] 胃肿瘤; DDX19A; 预后; UALCAN; Kaplan-Meier Plotter

DOI: 10.19401/j.cnki.1007-3639.2021.10.004

中图分类号: R735.2 文献标志码: A 文章编号: 1007-3639(2021)10-0899-06

Expression of RNA helicase DDX19A and its clinical significance in gastric cancer ZHANG Meizhizi, GUO Jiawen, ZHOU Lili, CHENG Yu (Basic Medical College of Chengde Medical College, Chengde 067000, Hebei Province, China)

Correspondence to: CHENG Yu E-mail: 369383126@qq.com

[Abstract] **Background and purpose:** RNA helicase DEAD-box helicase 19A (DDX19A), a member of the DDX protein superfamily, is mainly involved in the RNA transport process. Many members of this family are involved in the genesis and progression of tumors, however, the role of DDX19A in gastric cancer has not been reported. Combined with bioinformatics analysis, the expression of DDX19A in gastric cancer tissues and its clinical significance were investigated. **Methods:** The UALCAN database was used to analyze the expression difference of DDX19A in gastric cancer tissues and adjacent gastric tissues at the transcriptional level, and the relationship between its expression in gastric cancer and clinical stage was further analyzed. Kaplan-Meier Plotter database was used to analyze the correlation between DDX19A expression level and overall survival (OS) and disease-free survival (DFS) of gastric cancer patients. Western blot assay was used to detect the expression of DDX19A protein in 16 pairs of frozen fresh gastric cancer tissues and adjacent gastric mucosa. A total of 109 paraffin specimens of gastric cancer and 30 paracancerous

基金项目: 河北省科学技术厅2021年大中学生科技创新能力培育专项项目 (2021H080605); 河北省重点学科建设项目 [冀教高 (2013) 4号病理学与病理生理学]; 承德医学院2020年基本科研业务费课题 (KY2020011)。
通信作者: 程 玉 E-mail: 369383126@qq.com

gastric mucosa specimens were collected from Department of Pathology, Affiliated Hospital of Chengde Medical College from 2011 to 2015, and clinicopathological data of all patients were complete. Immunohistochemical S-P four-step method was used to detect the expression of DDX19A protein in 109 cases of gastric cancer and 30 cases of adjacent gastric mucosa. The relationship between the overexpression of DDX19A protein and the clinicopathological characteristics and prognosis of gastric cancer was statistically analyzed. **Results:** UALCAN and Kaplan-Meier Plotter database search results showed that DDX19A mRNA expression was significantly higher in gastric cancer tissues than in adjacent gastric tissues ($P < 0.01$), and its high expression was positively correlated with clinical stage and poor prognosis of gastric cancer patients ($P < 0.05$). Western blot results showed that DDX19A protein was significantly overexpressed in gastric cancer tissues ($P < 0.01$). Immunohistochemical experiments showed that the positive expression rate of DDX19A in gastric cancer tissues was 68.8% (75/109), which was significantly higher than that in paracancerous gastric mucosa (33.3%, 10/30) ($P < 0.01$). The high expression of DDX19A was closely related to the differentiation degree, infiltration depth and TNM stage of gastric cancer ($P < 0.05$), but not to gender, age, tumor size or lymph node metastasis ($P > 0.05$). In 69 cases with complete follow-up data, the OS of patients with high DDX19A expression was significantly lower compared with those with low DDX19A expression ($P < 0.05$). **Conclusion:** DDX19A is highly expressed in gastric cancer tissues, and is associated with clinical staging, invasiveness and poor prognosis of patients. It is expected to be a potential biomarker and a new therapeutic target related to the prognosis of gastric cancer.

[Key words] Gastric cancer; DDX19A; Prognosis; UALCAN; Kaplan-Meier Plotter

2018年,全球新发胃癌病例约1 000 000例,发病率位居第五,死亡病例约783 000例,死亡率位居第三^[1]。在中国,胃癌发病率和死亡率均高居第二位^[2]。胃癌发病十分隐匿,确诊时大多已到中晚期。通过了解胃癌的潜在发病机制和病因,将有助于发现胃癌晚期治疗和诊断的生物标志物。DDX19A(DEAD-box helicase 19A)作为RNA解旋酶DDX蛋白超家族的成员之一,被鉴定为一种新的细胞质RNA传感器,在病毒感染过程中可以激活NLRP3炎症小体^[3]。新近有文献^[4]报道,DDX19A通过诱导NOX1介导的ROS产生促进宫颈鳞状细胞癌(cervical squamous cell carcinoma, CSCC)转移。然而目前尚未明确DDX19A在胃癌中的表达及作用。本研究结合数据库检索资料,采用蛋白质印迹法(Western blot)及免疫组织化学法检测DDX19A在胃癌组织中的表达,分析其表达与胃癌临床病理学特征及预后的相关性。

1 资料和方法

1.1 临床资料

收集2011—2015年承德医学院附属医院病理科存档的胃癌组织(经4%的甲醛溶液固定后用石蜡包埋)标本109例,癌旁胃黏膜标本

30例,所有患者临床病理学资料完整。109例胃癌标本中男性83例,女性26例;年龄 ≤ 58 岁(中位年龄)者56例, > 58 岁者53例;肿瘤直径 ≤ 5.0 cm者59例, > 5.0 cm者50例;高-中分化52例,低分化57例;侵及浆膜层78例,未侵及浆膜者31例;有淋巴结转移62例,无淋巴结转移47例;TNM分期:I+II期57例,III期52例。109例胃癌标本中有69例具有完整的预后信息,随访时间为2~71个月,平均随访时间43.5个月。另收集16对新鲜胃癌与癌旁配对组织,置于 -80 °C超低温冰箱保存。本研究经承德医学院伦理委员会批准,所有纳入患者均知情同意。

1.2 主要试剂

BCA蛋白定量试剂盒、RIAP蛋白裂解试剂盒和蛋白酶抑制剂(PMSF)购自上海碧云天生物技术有限公司,免疫组织化学S-P试剂盒、DAB显色试剂盒购自北京中杉金桥生物技术有限公司;兔抗人DDX19A多克隆抗体、 β -actin鼠抗人单克隆内参抗体购自武汉华美生物工程有限公司。

1.3 方法

1.3.1 数据库

UALCAN (<http://ualcan.path.uab.edu>)是基于癌症基因组图谱(The Cancer Genome Atlas, TCGA)和MET500队列数据的交互式网络资源,可以用来分析肿瘤与正常组织相关基因的

表达及其与相关临床病理学参数的关系^[5]。Kaplan-Meier Plotter数据库源自高通量基因表达数据库(Gene Expression Omnibus, GEO)、欧洲基因组-表型组档案数据库(European Genome-phenome Archive, EGA)和TCGA的基因芯片和RNA-Seq数据,能评估54 000个基因对21种癌症类型生存率的影响^[6]。

1.3.2 Western blot

取适量于-80℃冰箱冻存的胃癌及配对正常胃黏膜组织,加入RIAP裂解液和蛋白酶抑制剂(100:1配比)后充分研磨。BCA试剂盒蛋白定量后,按比例加入loading buffer缓冲液煮沸10 min使蛋白变性。每孔60 μg总蛋白上样,经10%SDS-PAGE胶电泳后,75 V电压1.5 h将蛋白转移至PVDF膜上,5%脱脂奶粉封闭2 h,加入一抗DDX19A(1:2 000)和内参一抗β-actin(1:10 000)4℃摇床温育过夜。TBST洗膜10 min×3次后,二抗(1:5 000)常温温育1 h,洗膜后ECL显影。Image J软件计算灰度值。

1.3.3 免疫组织化学检测及判读

石蜡包埋组织4 μm厚连续切片,二甲苯脱蜡,梯度乙醇至水,柠檬酸高压修复2.5 min。按S-P免疫组织化学试剂说明书依次滴加A、B液,之后DDX19A(1:50)一抗4℃温育过夜。次日,滴加C、D液,DAB显色,苏木精染色。同时设立阴性对照及阳性对照。每张切片由2位高年资病理科医师分别独立阅片。参照文献^[7]判读标准,依据细胞染色深浅计分:不着色记0分,浅黄色记1分,棕黄色记2分,棕褐色记3分;依据阳性细胞数百分比:阳性细胞数<1%记0分,1%~25%记1分,26%~50%记2分,51%~75%记3分,76%~100%记4分;将两项得分相乘:≤4分记为低表达组,>4分记为高表达组。

1.4 统计学处理

所有实验数据的统计学分析均采用SPSS 20.0软件,采用Graph Prism 7.0软件绘制统计图。计数资料组间差异的比较及与临床病理学特征之间的关系采用χ²检验,计量资料采用 $\bar{x} \pm s$ 表示,组间差

异采用配对t检验。 $P < 0.05$ 为差异有统计学意义。

2 结果

2.1 UALCAN及Kaplan-Meier Plotter数据库分析

利用UALCAN数据库,转录水平分析DDX19A在415例胃癌组织及34例正常胃组织中的表达差异,发现DDX19A在胃癌组织中显著高表达($P < 0.001$,图1A)。进一步分析胃癌中DDX19A的表达与临床分期的相关性,发现胃癌的临床病理学分期越高,DDX19A的表达也越高(图1B)。检索Kaplan-Meier Plotter数据库发现,DDX19A基因高表达组胃癌患者总生存期(overall survival, OS)、无病生存期(disease-free survival, DFS)均明显短于低表达组,差异有统计学意义($P < 0.05$,图1C、D)。

2.2 Western blot法检测新鲜配对标本中DDX19A的表达

16对胃癌及癌旁配对标本中有12对(75%)的DDX19A蛋白表达水平明显升高(图2A)。经过灰度值计算,DDX19A蛋白在胃癌组织中的相对表达量为 3.57 ± 0.66 ,明显高于癌旁胃黏膜(1.58 ± 0.61),差异有统计学意义($P < 0.05$,图2B)。

2.3 免疫组织化学检测胃癌石蜡标本中DDX19A的表达

免疫组织化学结果显示DDX19A阳性表达主要定位于细胞质和细胞核。109例胃癌标本中,DDX19A高表达75例,阳性率为68.8%,其在胃癌组织中的表达明显高于癌旁胃黏膜(10/30, 33.3%)($P < 0.01$,表1)。如表2所示,DDX19A高表达与胃癌分化程度、浸润深度、TNM分期有关($P < 0.05$);而与患者性别、年龄、肿瘤大小、淋巴结转移无关($P > 0.05$)。结合随访资料,采用Kaplan-Meier法分析69例患者生存状态,log-rank检验发现DDX19A高表达的胃癌患者总生存期较短($P < 0.05$,图3)。

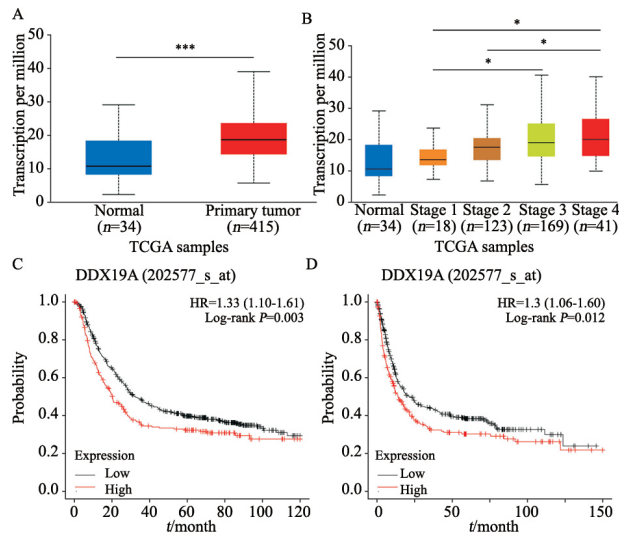


图 1 数据库分析DDX19A在胃癌中的表达水平及临床意义

Fig. 1 The expression and clinical significance of DDX19A in gastric cancer were analyzed by database

A: In UALCAN database, DDX19A was significantly highly expressed in gastric cancer tissues; B: Relationship between mRNA expression of DDX19A and cancer stages of gastric cancer patients (UALCAN); C: Kaplan-Meier Plotter database was used to analyze the relationship between DDX19A expression and overall survival (OS); D: Kaplan-Meier Plotter database was used to analyze the relationship between DDX19A expression and disease-free survival (DFS). *: $P < 0.05$, compared with each other; ***: $P < 0.001$, compared with each other

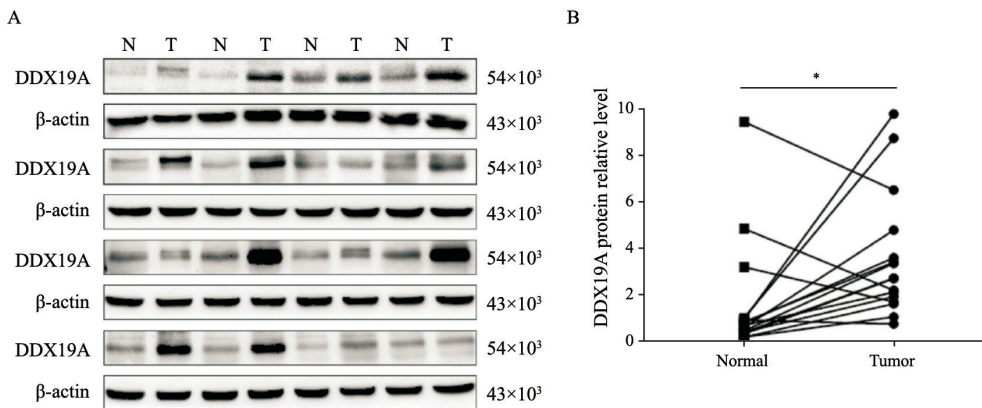
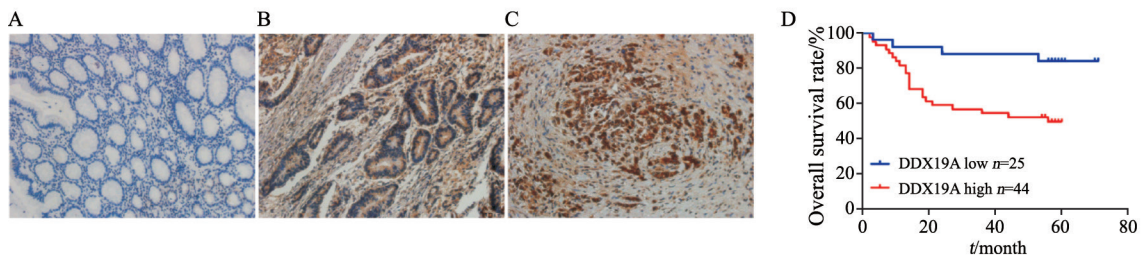


图 2 胃癌及癌旁胃黏膜中DDX19A的蛋白水平

Fig. 2 Level of DDX19A protein in gastric cancer and adjacent gastric mucosa

N: Gastric mucosa adjacent to cancer tissues; T: Cancer tissues; *: $P < 0.05$, compared with each other



(DAB, $\times 200$)

图 3 DDX19A蛋白在胃癌及癌旁胃黏膜的表达及预后价值

Fig. 3 Expression of DDX19A protein and its prognostic value in gastric cancer and adjacent gastric mucosa

A: Expression of DDX19A in gastric mucosa adjacent to cancer; B: Highly to moderately differentiated gastric cancer; C: Poorly differentiated gastric cancer; D: Relationship between DDX19A high expression and OS in 69 patients with gastric cancer

表1 癌旁胃黏膜及胃癌组织中DDX19A表达差异

Tab. 1 Difference of DDX19A expression in adjacent gastric mucosa and gastric cancer tissues

Group	Case	DDX19A		χ^2	P value
		Low	High		
Normal	30	20	10	12.462	0.000
Gastric cancer	109	34	75		

表2 胃癌组织中DDX19A高表达与临床病理学特征的相关性

Tab. 2 Correlation between high expression of DDX19A and clinicopathological features in gastric cancer

Clinicopathologic features	Case n	DDX19A		χ^2	P value
		Low	High		
Gender					
Male	83	28	55	1.048	0.306
Female	26	6	20		
Age/year					
≤58	56	17	39	0.037	0.847
>58	53	17	36		
Tumor size D/cm					
≤5.0	59	14	45	3.338	0.068
>5.0	50	20	30		
Differentiation degree					
Well-medium	52	30	22	32.535	0.000
Poor	57	4	53		
Invasion of serosa					
No	31	15	16	5.967	0.015
Yes	78	19	59		
Lymph node metastasis					
No	47	19	28	3.282	0.070
Yes	62	15	47		
TNM stage					
I + II	57	24	33	6.629	0.010
III	52	10	42		

3 讨 论

DEAD-box RNA解旋酶几乎存在于所有真核生物以及大多数细菌和一些古细菌中, 该家族属于RNA解旋酶中的第二超家族, 也是真核

生物RNA解旋酶中最大的一类^[8]。该家族蛋白以保守的氨基酸序列(Asp-Glu-Ala-Asp/His)命名, 能够以ATP酶依赖的方式释放和重组具有复杂二级结构的RNA分子。它们能重塑发夹结构和RNA蛋白复合体等复杂的RNA结构, 几乎在所有的mRNA处理和翻译步骤中扮演着关键的角色^[9]。DDX19A是一种重要的DEAD-box RNA解旋酶, 其在进化上高度保守的氨基酸序列预示着其存在强大的生物学功能。DDX19A定位于细胞核、细胞质, 在其蛋白质的N-末端识别出一个核输出信号和一个核输入信号, 使它们能够在隔层之间穿梭。本研究中免疫组织化学结果也证实DDX19A在组织中表达于细胞核和细胞质, 预示着其可能具有信号传输功能。DDX19A的活性中心由两个高度保守的类RecA结构域组成, 这两个结构域由一个铰链区连接, 其N末端延伸对其自身调节非常重要, 决定了酶的特异性^[10]。

癌细胞严重依赖RNA解旋酶来满足不断增加的一般蛋白质合成需求, 而且也需要翻译特定的致癌因子mRNA来提高存活率^[9]。鉴于DEAD-box RNA解旋酶对RNA的强大调控作用, 越来越多的研究^[11-15]证实该家族成员在肿瘤的发生及发展过程中扮演重要角色。

最近, 有文献^[4]报道, DDX19A在CSCC组织中高表达, DDX19A高表达与癌细胞转移和患者不良临床预后呈正相关, 体外实验证实DDX19A可促进CSCC细胞的迁移和侵袭。然而, 到目前为止, DDX19A在胃癌中的作用尚不清楚。因此, 我们分析了DDX19A在胃癌组织中的表达及临床意义, 采用Western blot及免疫组织化学法检测DDX19A在胃癌组织及癌旁胃黏膜的表达, 发现胃癌中DDX19A的表达显著高于癌旁对照组, 此结果与UALCAN数据库结论相符。DDX19A高表达与胃癌临床病理学特征相关, 患者临床表现越差, 即分化越低、浸润越深、分期越高, DDX19A的表达水平越高, 并且DDX19A高表达的患者OS较短。这与Kaplan-Meier Plotter数据库检索结果DDX19A高表达患者OS及DFS较短一致。以上结果提示DDX19A极有可能作为一

个新的原癌基因, 参与调控胃癌的发生及发展过程, 促进胃癌的恶性进展。

当然, 本实验不可避免地也存在不足之处:

① 样本量过少, 存在选择偏倚的可能性, 有待扩大样本量进一步研究。② 未进行体外细胞功能实验、体内实验及深入的作用机制研究。未来有必要深入探究DDX19A对胃癌细胞恶性表型的影响及其作用机制, 为胃癌的诊断和治疗提供新的线索。

[参 考 文 献]

- [1] SIEGEL R L, MILLER K D, FUCHS H E, et al. Cancer statistics, 2021 [J]. *CA Cancer J Clin*, 2021, 71(1): 7-33.
- [2] CHEN W, ZHENG R, BAADE P D, et al. Cancer statistics in China, 2015 [J]. *CA Cancer J Clin*, 2016, 66(2): 115-132.
- [3] LI J N, HU L, LIU Y Y, et al. DDX19A senses viral RNA and mediates NLRP3-dependent inflammasome activation [J]. *J Immunol*, 2015, 195(12): 5732-5749.
- [4] JIANG Y H, WANG B B, LI Y L, et al. DDX19A promotes metastasis of cervical squamous cell carcinoma by inducing NOX1-mediated ROS production [J]. *Front Oncol*, 2021, 11: 629974.
- [5] CHANDRASHEKAR D S, BASHEL B, BALASUBRAMANYA S A H, et al. UALCAN: a portal for facilitating tumor subgroup gene expression and survival analyses [J]. *Neoplasia*, 2017, 19(8): 649-658.
- [6] NAGY Á, LÁNCZKY A, MENYHÁRT O, et al. Validation of miRNA prognostic power in hepatocellular carcinoma using expression data of independent datasets [J]. *Sci Rep*, 2018, 8(1): 9227.
- [7] 董 兵, 朴俊杰, 杨 洋, 等. 胃癌中HSDL2过表达与临床病理特征的相关性 [J]. *临床与实验病理学杂志*, 2020, 36(1): 1-6.
- [8] DONG B, PIAO J J, YANG Y, et al. Correlation between HSDL2 overexpression and clinicopathological features in gastric cancer [J]. *Chin J Clin Exp Pathol*, 2020, 36(1): 1-6.
- [9] MIKHAILOVA T, SHUVALOVA E, IVANOV A, et al. RNA helicase DDX19 stabilizes ribosomal elongation and termination complexes [J]. *Nucleic Acids Res*, 2017, 45(3): 1307-1318.
- [10] HEERMA VAN VOSS M R, VAN DIEST P J, RAMAN V. Targeting RNA helicases in cancer: the translation trap [J]. *Biochim Biophys Acta Rev Cancer*, 2017, 1868(2): 510-520.
- [11] BEIBEL C, GROSSE S, KREBBER H. Dbp5/DDX19 between translational readthrough and nonsense mediated decay [J]. *Int J Mol Sci*, 2020, 21(3): E1085.
- [12] ZHU Y J, DU Y C, ZHANG Y D. DHX33 promotes colon cancer development downstream of Wnt signaling [J]. *Gene*, 2020, 735: 144402.
- [13] SANTORIELLO C, SPORRIJ A, YANG S, et al. RNA helicase DDX21 mediates nucleotide stress responses in neural crest and melanoma cells [J]. *Nat Cell Biol*, 2020, 22(4): 372-379.
- [14] LIN T C. DDX3X is epigenetically repressed in renal cell carcinoma and serves as a prognostic indicator and therapeutic target in cancer progression [J]. *Int J Mol Sci*, 2020, 21(8): E2881.
- [15] 李 斌, 蔺军平, 冯海明, 等. DDX46调控食管鳞癌TE-11细胞恶性生物学行为的机制探讨 [J]. *中国癌症杂志*, 2018, 28(9): 671-678.
- LI B, LIN J P, FENG H M, et al. The role of DDX46 in regulating the malignant process of esophageal carcinoma TE-11 cells [J]. *China Oncol*, 2018, 28(9): 671-678.
- [15] HE C C, LI A M, LAI Q H, et al. The DDX39B/FUT3/TGF β R-I axis promotes tumor metastasis and EMT in colorectal cancer [J]. *Cell Death Dis*, 2021, 12(1): 74.

(收稿日期: 2021-05-06 修回日期: 2021-09-25)